

# Boxers Fracture Treated with Antegrade Prebent K Wire Vs Conservative Management in Young Adults

Sandip Patil<sup>1</sup>, Sapan Vora<sup>1</sup> and Rohan Chavan<sup>1\*</sup>

<sup>1</sup>Krishna Institute of Medical Science, Karad, Satara, Malkapur, PIN-415539, India.

## Authors' contributions

This work was carried out in collaboration among all authors. Author SP designed the study, performed the statistical analysis, wrote the protocol and wrote the first draft of the manuscript. Authors SV and RC managed the analyses of the study. Author RC managed the literature searches. All authors read and approved the final manuscript.

## Article Information

### Editor(s):

(1) Dr. Ikem, Innocent Chiedu, Professor, Department of Orthopaedic Surgery and Traumatology, Obafemi Awolowo University, Ile-Ife, Nigeria.

### Reviewers:

- (1) Diana Cassi, University of Modena and Reggio Emilia, Italy.
  - (2) Vijaya Krishnan, Maharashtra University of Health Sciences, India.
  - (3) Yogesh Salphale, Chandrapur Multispecialty Hospital, India.
- Complete Peer review History: <http://www.sdiarticle4.com/review-history/52502>

Received 01 November 2019

Accepted 04 January 2020

Published 25 January 2020

Case Study

## ABSTRACT

**Introduction:** A prospective study of boxer's fracture treated with antegrade prebent K wire and conservatively in young adults.

**Materials and Methods:** In Krishna Institute of Medical Science Karad Satara from July 2017 to July 2019, 20 patients of 5th metacarpal neck fracture were studied, 10 were treated with antegrade prebent K wire and 10 treated conservatively were selected, children younger than 15 yrs and fracture involving articular surface were excluded.

**Observation:** Boxers fracture are 20% of fracture encountered in hand majority of patients are male with right hand involvement majority of cases were due to hitting an hard object with closed fist.

**Conclusion:** Percutaneous fixation with prebent K wire in antegrade direction gives better results as compared to conservative management which is usually associated with shortening and angular deformities.

Keywords: Boxer fracture; fixation; management.

\*Corresponding author: Email: [rohanslifeortho@gmail.com](mailto:rohanslifeortho@gmail.com);

## ABBREVIATIONS

TAM : Total Active Movement;  
DIP : Distal Interphalangeal Joint;  
PIP : Proximal Interphalangeal Joint;  
MCP : Metacarpo Phalangeal Joint.

## 1. INTRODUCTION

- Among all metacarpal fracture, fracture of 5<sup>th</sup> metacarpal neck is commonest [1,2,3].
- Also known as scrappers fracture, bar room fracture, street fighters fracture [4,3].

### 1.1 Pathomechanics

Impact of clinch fist to an hard object like skull or wall. Punch with improper form, forces act at an angle towards the palm, Dorsal bent in bone which causes fracture.

**Fracture of 4<sup>th</sup> & 5<sup>th</sup> metacarpal more common than 2<sup>nd</sup> and 3<sup>rd</sup> metacarpal because:** Normally :- Boxers punches with proper form, Knuckles of 2<sup>nd</sup> & 3<sup>rd</sup> metacarpal align linearly with articulating radius followed with humerus thus force travel across joints without injury [1].

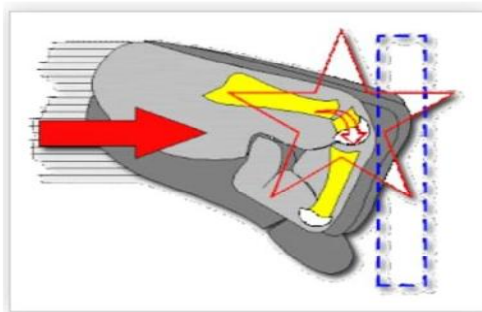


Fig. 1. Mechanism of Injury

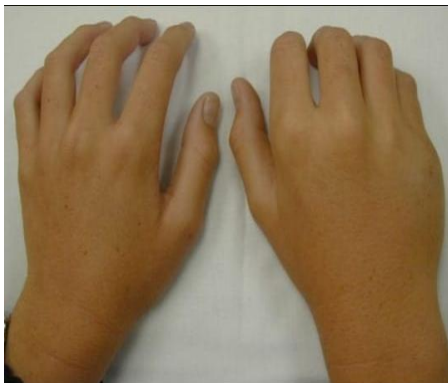

Fig. 2. Clinical presentation

## Emergency Management

1. Rest
2. Ice pack
3. Sling
4. Elevation

## 2. MATERIALS AND METHODS

- 20 patients of fracture of 5<sup>th</sup> metacarpal were studied in Department of Orthopaedics, Krishna Institute of Medical Science Karad, Satara from July 2017 to July 2019.
- 10 were treated with antegrade k wire and 10 were treated conservatively
- Children younger than 15 yrs were excluded
- Articular fracture were exclude.

### 2.1 Methods

- For 5<sup>th</sup> metacarpal, entry point of k wire or awl or drill is dorsoulnar at metacarpal base without damaging the carpo-metacarpal joints & respecting the insertion of extensor carpi ulnaris tendon.

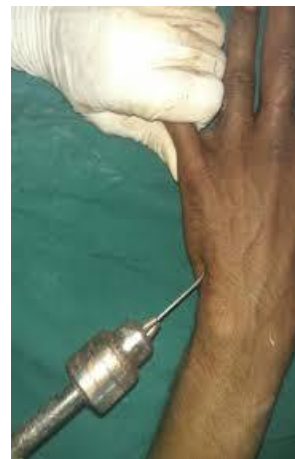

Fig. 3. Antegrade k wire in boxers fracture

- Care must be taken that the protruding end of K wire or bone awl or drill does not interfere with the gliding extensor tendon.
- Pre bending of K wire
- Distal tip of K wire is bent to about 20° about 2 cm from there the wire is bent to about 10°
- Fixation using 2 K wire gives 2 point fixation thus increasing the stability & prevent back out of K wire from proximal end.

Conservative treatment included splinting as follows: mild wrist extension, 70 to 90 degrees of flexion at MCP joint [5,6,7], and slight flexion at the DIP and PIP joints. Flexion of these joints is important to prevent shortening of the collateral ligaments and subsequent loss of range of motion and functional impairment [8] (Fig.7.)

## 2.2 Follow Up

Post operative the patient were assessed at 4<sup>th</sup> week, 6<sup>th</sup> week, 8<sup>th</sup> week and 12<sup>th</sup> week

- At every follow up TAM (Total Active Movement) was noted at

metacarpophalyngeal joint & interphalyngeal joint.

- Total active movement = total active flexion – total extension deficit.
- TAM=total active flexion (metacarpophalyngeal joint + proximal interphalyngeal joint + distal interphalyngeal joint)-total extension deficit (metacarpophalyngeal joint+ proximal interphalyngeal joint+distal interphalyngeal joint).
- Rotation deformity was noted at neck shaft angle preoperatively & postoperatively percentage of angular correction was assessed and was compared with conservative treatment.

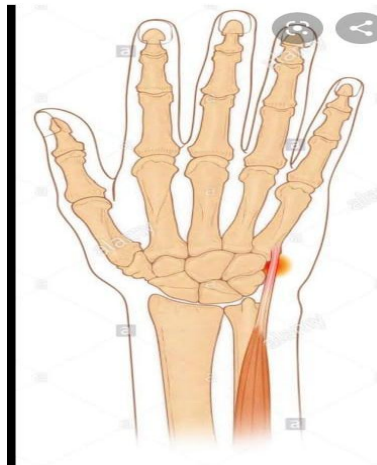

Fig. 4. Extensor carpi ulnaris tendon

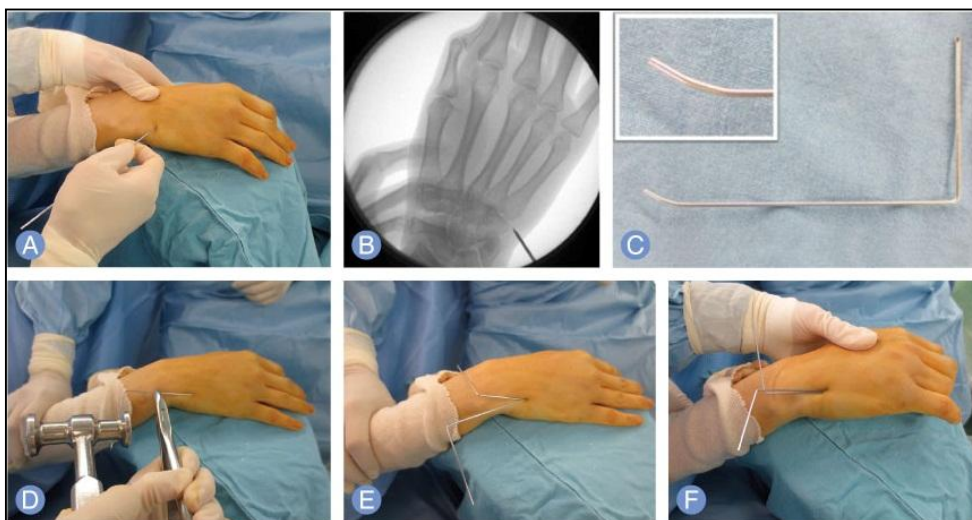

Fig. 5. Procedure performed

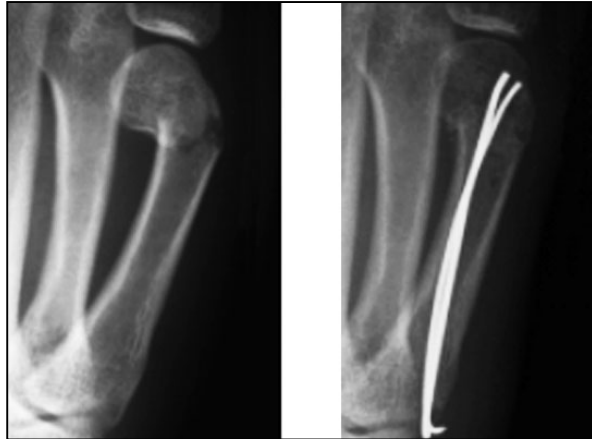


Fig. 6. XRAY with 2 k wire's showing angular correction immediately after operation

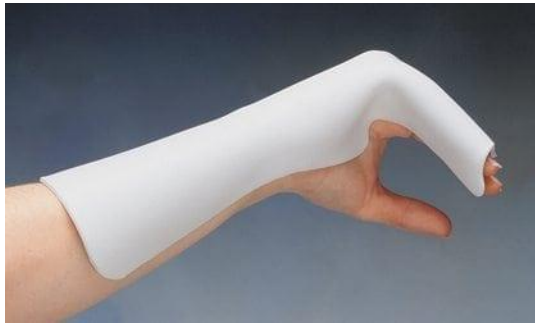

Fig. 7. Conservative management

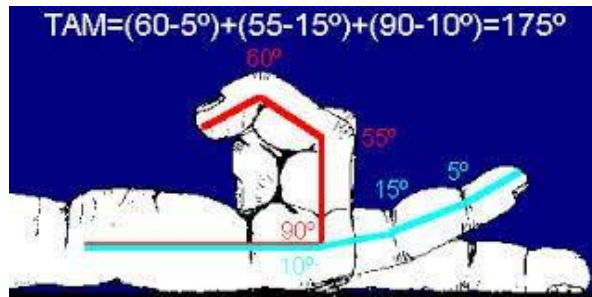


Fig. 8. Calculation of tam

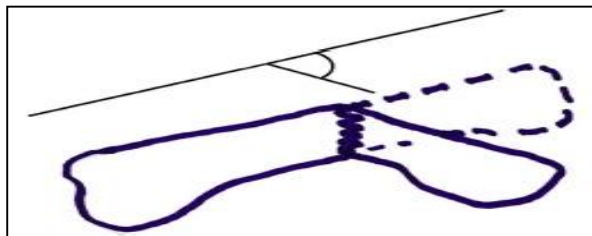


Fig. 9. Calculation of neck shaft angle

### 3. RESULTS

- Out of 20 patients of fracture of 5<sup>th</sup> metacarpal were studied in Department of Orthopaedics, Krishna Institute of Medical Science Karad, Satara from July 2017 to July 2019.
- The mean TAM of affected hand on last follow up was recorded and was compared with unaffected hand, percentage of improvement was compared with percentage of improvement of TAM in conservative management with respect to neck shaft angle
- We found that at last follow up (3rd month) there was no significant difference in TAM (Total Active Movement) of affected and unaffected hand in patients treated with antegrade k wire technique.
- Conservative management was associated with shortning and malrotation.
- We also found out that person having neck shaft angle more than 45 degrees shows

better result when treated with antigrade k wire.

- People having neck shaft angle less than 30 degrees can be treated conservatively.

**Table 1. Demography**

Mean Age	32 ± 2.2
Sex Male/Female	6:1
Right/Left	16/4

### 4. DISCUSSION

- Neck Shaft angle more than 45° produces significant muscle restriction that can limit movements of 5th digit but a fracture angle of 30° is compatible with normal function.
- Displacement of head in direction of flexion tends to heel poorly as a result of deforming forces of intrinsic muscles.
- Surgery is indicated when there is clinical malrotation of 5th finger & shortening.

**Table 2. Treatment using antegrade K-Wire**

Pt No.	TAM of affected hand on last follow up	TAM of unaffected hand on last follow up	% of improvement	Preop neck shaft angle	Post of neck shaft angle
1	270	275	98	65	25
2	255	260	98	60	18
3	300	305	98	68	16
4	290	290	100	70	20
5	278	282	98	55	16
6	295	300	98	52	22
7	278	282	98	64	20
8	270	275	98	58	24
9	260	265	98	65	15
10	300	305	98	60	20
Mean	279	283	98	61	19

**Table 3. Conservative management**

PT no	Tam of affected hand on last follow up	Tam of un-affected hand on last follow up	Percentage of improvement	Neck shaft angle	Neck shaft angle at end of 3 months
1	252	280	90	64	55
2	262	282	93	65	49
3	268	280	96	30	25
4	282	300	94	45	35
5	266	280	95	35	25
6	276	282	98	35	20
7	268	280	96	35	20
8	255	300	85	64	50
9	285	300	95	30	24
10	280	286	98	32	18
Mean	269	287	94	43	32

## 5. CONCLUSION

- Boxers Fracture are common type fracture in young adults. Conservative management can cause shorting and angular deformities and decrease in hand grip.
- Antegrade prebent K wire help in angular correction and gives better result when compared with conservative management especially in patients having clinical malrotation and shortning.
- Use of two K-wires helps in good fixation and stability to fracture site.

## CONSENT AND ETHICAL APPROVAL

As per international standard guideline participant consent and ethical approval has been collected and preserved by the authors.

## COMPETING INTERESTS

Authors have declared that no competing interests exist.

## REFERENCES

1. Mohammed R, Farook MZ, Newman K. Percutaneous elastic intramedullary nailing of metacarpal fractures: Surgical technique and clinical results study. J Orthop Surg Res. 2011;6:37.
2. Yammine K, Harvey A. Antegrade intramedullary nailing for fifth metacarpal neck fractures: A systematic review and metaanalysis. Eur J Orthop Surg Traumatol. 2014;24:273-8.
3. Hunter JM, Cowen NJ. Fifth metacarpal fractures in a compensation clinic population: A report on one hundred and thirty-three cases. J Bone Joint Surg Am. 1970;52:1159-65.
4. Gudmundsen TE, Borgen L. Fractures of the fifth metacarpal. Acta Radiol. 2009; 50(3):296-300.
5. Ali A, Hamman J. Mass DP. The biomechanical effects of angulated boxer's fractures. J Hand Surg Am. 1999;24:835-44.
6. Cepni SK, Aykut S, Bekmezci T, Kilic A. A minimally invasive fixation technique for selected patients with fifth metacarpal neck fracture. Injury. 2016;47(6):1270-5.
7. Diaz-Garcia R, Waljee JF. Current management of metacarpal fractures. Hand Clin. 2013;29:507-18.
8. Kim JK, Kim DJ. Antegrade intramedullary pinning versus retrograde intramedullary pinning for displaced fifth metacarpal neck fractures. Clin Orthop Relat Res. 2015; 473(5):1747-54.
9. Wong TC, Ip FK, Yeung SH. Comparison between percutaneous transverse fixation and intramedullary K-wires in treating closed fractures of the metacarpal neck of the little finger. J Hand Surg Br. 2006; 31:61-5.
10. Facca s, Ramdhian R, Pelissier A, Diaconu M, Liverneaux P. Fifth metacarpal neck fracture fixation: Locking plate versus K-wire? Orthop Traumatol Surg Res. 2010; 96:506-12.

© 2020 Patil et al.; This is an Open Access article distributed under the terms of the Creative Commons Attribution License (<http://creativecommons.org/licenses/by/4.0>), which permits unrestricted use, distribution, and reproduction in any medium, provided the original work is properly cited.

*Peer-review history:*

*The peer review history for this paper can be accessed here:  
<http://www.sdiarticle4.com/review-history/52502>*